

## Modification in Orthodromic Transfer of the Temporalis Muscle for the Treatment of Long-Standing Facial Paralysis

AMIR ELBARBARY, M.D.

*The Department of Plastic & Reconstructive Surgery, Faculty of Medicine, Ain-Shams University.*

### ABSTRACT

A modification in temporalis muscle transfer for lower facial reanimation of five consecutive cases with long-standing facial paralysis is presented. Instead of the traditional stripping of the temporalis from its origin, its insertion is detached from the coronoid through an intraoral approach. To reanimate the corner of the mouth, these fibers were then sutured to a fascia lata graft that passed to the Orbicularis Oris. The procedure is less extensive and provides a direct "orthodromic" line of pull with good functional results. This simple procedure has helped reconstruction of natural symmetrical smile with successful results.

### INTRODUCTION

The treatment of long-standing facial paralysis through transposition of regional muscles has been known for almost a decade [1]. The objective being the transfer of muscle innervated by a nerve other than the facial nerve. The goal is facial symmetry at rest and with voluntary smiling [2]. The muscle used most frequently is the temporalis muscle [3,4], innervated by the trigeminal nerve and thus not compromised by a facial nerve lesion or injury.

Gillies [5] was the first to propose detachment of temporalis from its origin followed by its inversion over the zygomatic arch. A graft of fascia lata bridged the muscle to the nasolabial sulcus. This antidromic transposition resulted in extra bulge over the zygomatic arch and caused distinct facial asymmetry. Several modifications were introduced to overcome this problem [6-9]. However, it was not until 1953 when McLaughlin [10] proposed inline "orthodromic" transposition of the temporalis muscle without changing its direction. Preserving the muscle direction (i.e., orthodromic) results in good muscular excursion and power. The muscle was freed inferiorly, by osteotomy of the coronoid process, through an intraoral approach. The muscle was passed below the zygomatic arch and extended

by a fascia lata graft sutured to the orbicularis oris muscle, thus pulling at the corner of the mouth. The inconvenience of the intraoral route, operating through a small window with a bone saw, stimulated Breidahl and colleagues [11] to perform a similar procedure, using an extraoral approach. However, this necessitated partial resection of the zygomatic arch to visualize the muscle tendon. This method resulted in greater facial symmetry and depression at the arch because of the absence of bone [2]. Recently, Viterbo & Faleiros [2] recommended the orthodromic transposition without removing bone of the zygomatic arch and with minimal muscle manipulation. Although, theoretically appealing, it is technically difficult to reach to the insertion without cutting the arch. Quite often, the arch has to be removed before it was repositioned and fixed back at the end of the procedure [12]. Needless to say that this adds to the surgical time with increased risks of both intraoperative bleeding and injuring the temporalis innervations and that the external scars are always undesirable.

Trying to improve on these methods, a modification in the orthodromic transposition of the temporalis muscle was developed. It included essentially McLaughlin's [10] intraoral approach but without performing the osteotomy of the coronoid process. While this modification make use of the advantage of the orthodromic transposition of the temporalis muscle in terms of better muscle excursion and power, it offer simplicity to the technique with good esthetic results and less surgical time.

### *Aim of work:*

The aim of this follow-up study is to evaluate the clinical usefulness of a modified orthodromic transposition of the temporalis muscle in treating long-standing facial palsy through stripping its

insertion off the coronoid process using an intraoral approach.

## MATERIAL AND METHODS

In five consecutive patients suffering from long-standing facial paralysis, a modified technique in orthodromic transposition of the temporalis muscle through an intraoral approach was applied at the Department of Plastic and Reconstructive Surgery, Ain-Shams University Hospital between July 2007 and July 2008. All patients in the study population were managed using the same protocol. The power of the temporalis muscle was confirmed by asking the patient to clench their teeth. The direction and extent of smile on the normal side was analyzed (Fig. 1). This was done in order to apply the vector of pull on the reconstructed side mimicking, as much as surgically feasible, the movement on the patient's normal side. Criteria of exclusion included patients with the primary smile vector in the direction of pull of the buccinators-risorius complex since they are better managed by masseter transposition.

Treatment was undertaken under general anesthesia with nasoendotracheal intubation. The position of the patient was supine, with the face turned toward the normal side. A bite block was inserted between the molars of the normal side to maintain mouth opening during intraoral component of the procedure. The coronoid process with the insertion of the temporalis muscle was exposed using an intraoral incision made over the anterior border of the ascending ramus. The incision was carried down through the periosteum and extended no more superior than the occlusal plane of mandibular teeth to help prevent herniation of the buccal fat pad into the surgical field. Subperiosteal dissection was done superiorly till reaching the glistening insertion of temporalis at the coronoid. Stripping the insertion of the muscle was done meticulously while holding it with several prolene 3/0 sutures to avoid its cephalad retraction. A 3-cm incision at the nasolabial fold was done where the orbicularis oris muscle was exposed. Wide subcutaneous undermining was done cephalad creating a tunnel superficial to the SMAS that is connected to the intraoral incision (Fig. 2). A fascia lata graft, 3 x 10cm, was harvested and sutured to the insertion of the temporalis. The graft was passed into the subcutaneous tunnel and its caudal end was sutured with overcorrection to the modiolus at the corner of the mouth. At this point, the graft was split and each half passed for a few centimeters into the corresponding lip (Fig. 3) and sutured along multiple superficial and deep points into the orbicularis

oris using prolene 4/0 sutures. The graft was also sutured into the dermis at the nasolabial fold.

During the immediate postoperative period, soft diet for 30 days was recommended. The patients were instructed to consciously clench their teeth in front of a mirror in conjunction with smiling. They were also instructed to exercise maximum mouth opening and closure several times a day to overcome any anticipated scarring at the site of muscle insertion detachment at the coronoid.

Duration and causes of facial paralysis were recorded. Outcomes measured included patient satisfaction, objective measurements of oral commissure elevation with smiling and physician grading of preoperative and postoperative patient photographs. The grading classification by Viterbo & Faleiros [2] and May [3,13] was adopted: 1, excellent (patient smiles voluntarily with exposure of the teeth); 2, good (discreet smile, pulling up the corner of the mouth); 3, average (facial asymmetry at rest) and 4, bad (no change). Postoperative complications were evaluated.

## RESULTS

The study population included four female patients and one male patient with old unilateral facial paralysis. The mean age of patients was 23.7 years (range, 18 to 39 years). The mean duration of paralysis was 12.4 years (range, 8 to 20 years). Causes of facial paralysis included Bell's palsy in three cases, one congenital case and post traumatic for the remaining case.

In the first week after surgery the patients showed edema and in some cases ecchymoses, which generally cleared by the end of the second week. Approximately a couple of months later, any overcorrection resolved and the corner of the mouth descended to a normal position (Figs. 4,5).

Patient satisfaction was high, with a mean score of 8.5 (out of 10). Four patients were physician graded as good. The other patient was rated as having excellent postoperative result. Movement was identified in every patient and ranged from 4.5 to 10.5mm, with mean movement of the oral commissure of 8.2mm. One patient developed postoperative infection at the nasolabial fold incision and was treated with antibiotics. No complaints of paresthesia, hyposthesia or scar on donor leg were noticed. None of the patients required a revision of surgery for unacceptable contour or asymmetry. No muscle compromise has been observed, since the innervation and vascularity were maintained.

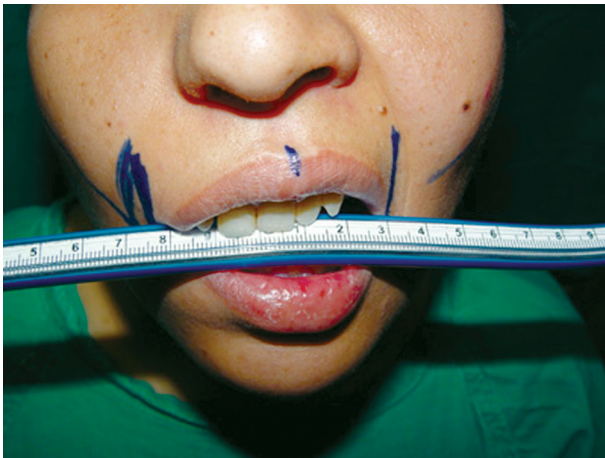

Fig. 1-A

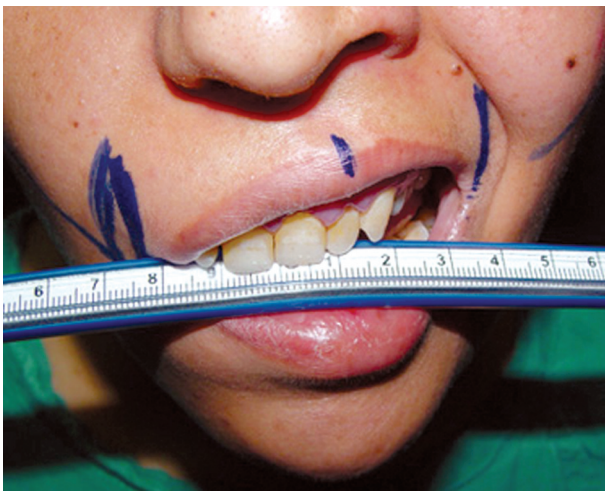

Fig. 1-B

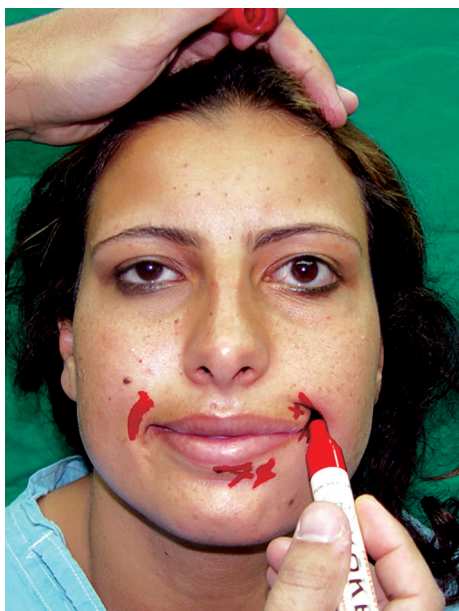

Fig. 1-C

Fig. (1): Analysis of direction and extent of smile on the normal side. Measuring the distance from the interincisal point till commissure at rest (A) and during smiling (B). Marking of the vector of pull and nasolabial crease at the paralyzed side (C).

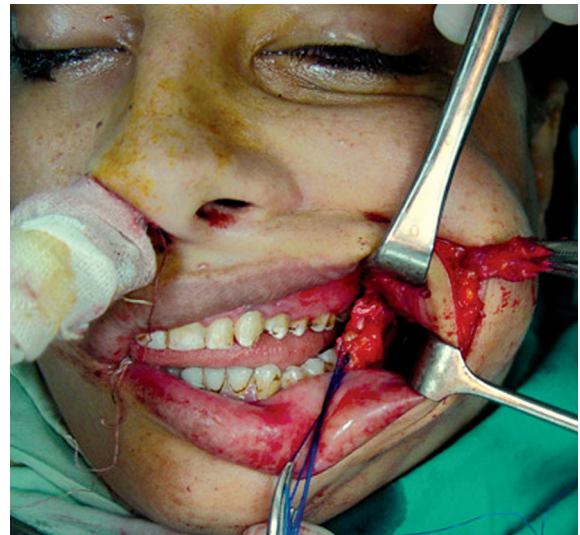

Fig. (2): A fascia lata graft, sutured to the insertion of the temporalis intraorally and passed through a supra-SMAS tunnel to reach the nasolabial crease.

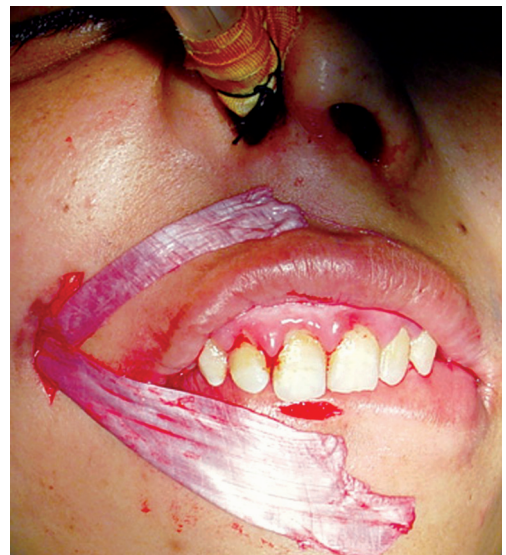

Fig. 3-A

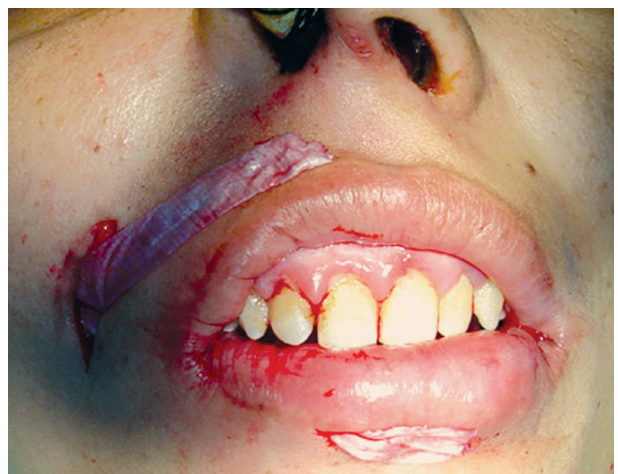

Fig. 3-B

Fig. (3): The fascia lata graft was split and each half passed for a few centimeters into a subcutaneous tunnel to the corresponding lip.

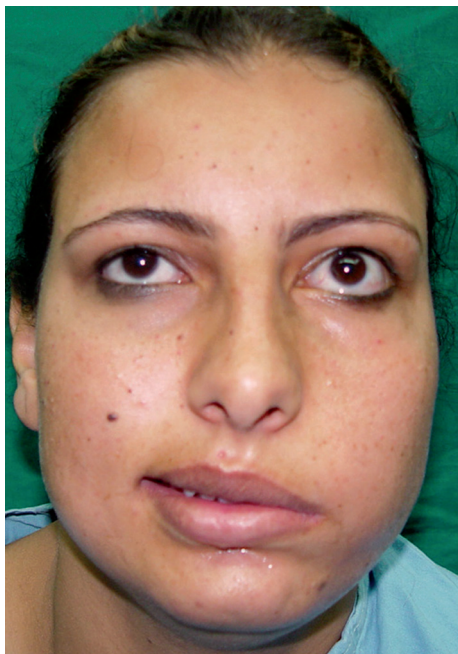

Fig. 4-A

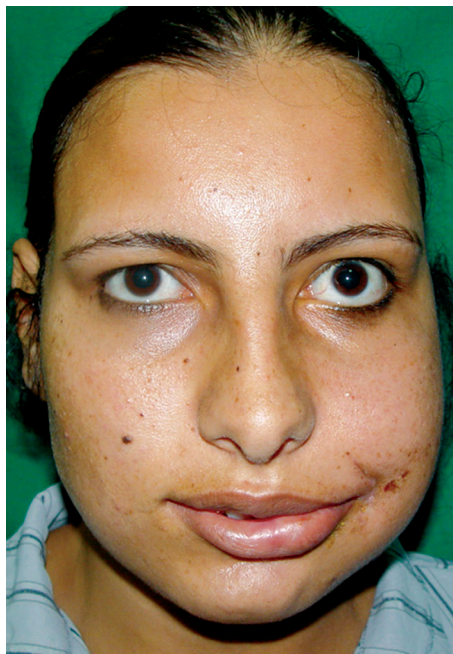


Fig. 4-B

Fig. (4): Left congenital facial palsy. Left, Before surgery. Right, 3 weeks after surgery.

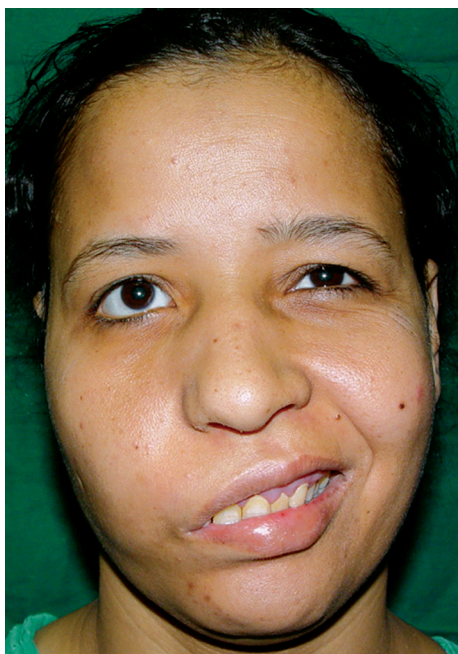

Fig. 5-A

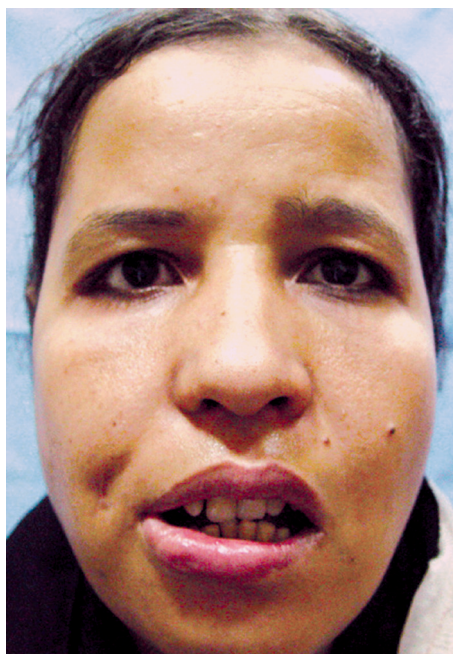

Fig. 5-B

Fig. (5): Right congenital facial palsy. Left, Before surgery. Right, 9 months after surgery.

## DISCUSSION

While facial expression is imperative to communication, facial paralysis has serious physical and emotional ramifications [14]. When the mouth is affected, facial paralysis hinders the patient's ability to smile symmetrically. Paralysis of the orbicularis oris muscle leads to incompetence,

which manifests as ipsilateral spillage of food and liquids along with difficulty with pronunciation of words that require pursing of the lips. Loss of tone in the buccinator muscle leads to masticatory problems due to difficulty with clearance of food from the ipsilateral gingival buccal sulcus and may cause trauma to the mucosa [15].

Many techniques have been proposed for the treatment of long-standing facial paralysis. This denotes that there is not yet one universal method for its treatment [2]. The major objectives of lower facial reanimation are to achieve symmetry at rest, oral sphincteric competence and facial movement [3]. Static slings achieve symmetry at rest [16,17]. However, it is the preservation of facial muscles that maintain symmetry upon smiling. Unfortunately, facial muscles of expression are atrophied in cases of long-standing paralysis and nerve grafting procedures alone do not represent an appropriate line of treatment. In these cases, transplants or muscle transpositions are indicated. Muscle transplant surgery is demanding, requiring microsurgical techniques, and the training of a surgical team. On the other hand, a muscle transposition presents a simpler procedure with predictable results [18].

Temporalis and masseter muscle transpositions have long been used in attempts to reanimate the face in long-standing facial paralysis [13,19-22]. The choice of the appropriate muscle for transfer is based on the main vector of the contralateral smile [23,24]. In all patients included in this study, the principle vector of the contralateral smile was superolateral in the direction of pull of the zygomaticus major muscle. Therefore, transposition to reanimate the corner of the mouth, allowing a smile was done using the temporalis muscle. In one patient, that was encountered during the study but not included, the primary vector was in the direction of pull of the buccinators-risorius complex and he was managed by masseter transposition.

All patients exhibited positive bell's phenomenon and were sent to an ophthalmologist for gold weight [25] application to close the eyelids rather than using the temporalis. This is in accordance with Casler and Conley's [26] "dual reanimation" system, addressing the eye and mouth with independent surgical procedures. It was found that if a single muscle was used to reanimate more than one anatomic region, mass action becomes unavoidable. The old saying "mass action is better than no action" is no longer true for these patients [14]. The best functional and cosmetic outcomes are provided when using the dual-system reanimation [26]. Furthermore, May & Drucker [3], whom have reported one of the largest series of temporalis transfers in the literature, concluded that better reanimation of the eye was achieved by techniques other than temporalis transfer. They use temporalis transfer exclusively for lower facial reanimation.

The antidromic transposition of the temporalis muscle with traditional stripping from its origin

was first proposed by Gilles [5]. A graft of fascia lata bridged the muscle to the oral commissure. Thus, when the patient would bite, the temporal muscle would contract, pulling up the corner of the mouth and mimicking a smile. Andersen [6] used deep temporal fascia, instead of the fascia lata, a method further proposed by Rubin [7]. Baker and Conley [8] used the pericranium in continuity with the origin of the temporalis muscle to increase the length of the flap, avoiding grafts of fascia. In all these antidromic temporalis transpositions, the muscle requires extensive dissection and folding it inferiorly produced bulge over the zygomatic arch. This bulge was further accentuated by the unattractive hollowness in the temple at the site of harvest causing distinct facial asymmetry and thus a major esthetic loss [9,11]. Furthermore, expanded surgical time is required and there are the associated risks of intraoperative bleeding and injury to the temporalis innervation. May [9] modified the technique, transposing the middle third of the temporalis muscle to minimize the bulging at the zygomatic arch. He used Gore-Tex tape to reach the corner of the mouth. May & Drucker [3] advocated a wider tunnel to accommodate the muscle to lie flat within it, thus decreasing the residual asymmetry.

The osteotomy of the coronoid through the mouth and the traction of the muscle around the mouth, proposed by McLaughlin [10] represent an advance in terms of transposition of the temporal muscle. Preserving the muscle direction (i.e., orthodromic) results in good muscular excursion and power. However, because of using a bone saw through a small intraoral operating window, the procedure was never popular [2]. Breidahl & colleagues [11] tried to solve this problem by performing an extraoral approach and performing an osteotomy of the zygomatic arch to visualize the temporalis muscle tendon. This method led to greater facial symmetry because the bulge at the arch was rather replaced by a depression. The Viterbo & Faleiros [2] modification of the extraoral orthodromic transposition is technically demanding while the Labbé and Huault [12] muscle lengthening needs greater muscle manipulation.

The modification presented in this study takes into account the advantages of the orthodromic (i.e., inline transposition of the temporalis muscle) in terms of better muscle excursion & power [2], without removing neither bone of the zygomatic arch nor the coronoid and with minimal muscle manipulation. The intraoral incision is a well hidden scar and provides good access to the operative field. It offers simplicity to the technique with

good esthetic results and less surgical time. Finally, detaching the temporalis insertion intraorally avoids injuring innervations of the muscle that could result when performing it extraorally [27].

Placing an incision externally in the nasolabial fold was done to enhance symmetry as advocated by Baker & Conley [8]. Suturing the fascia lata to the dermis at the nasolabial fold was made to enhance accentuation of the fold when the muscle was activated by clenching of the teeth as promoted by Anderson [14]. Attaching the facial bands to the modiolus and to multiple superficial and deep points along the orbicularis oris was done to improve the overall aesthetic result in agreement with Duckert & Cummings [22]. This is opposing to Viterbo & Faleiros [2] whom believe that double fixation of the fascia to both lower and upper lip could result in undesirable opening of the mouth. Unlike Viterbo & Faleiros's [2] technique that sutured the graft to the temporalis last, suturing the fascia to the temporalis tendon was done first in this study. This was technically more feasible when ensuring the overcorrection since the intraoral approach was used.

In this study, good movement of the corner of the mouth with restoration of smile was achieved upon clenching. Anderson [14] believes that the success rate is almost guaranteed provided the patient is consciously contracting the transposed muscle in conjunction with smiling. However, an interesting phenomenon of trigeminal neo-neurotization may be responsible for several cases reported in the literature in which patients achieved mimetic and more organized facial movement than would be expected following segmental temporalis muscle transfer alone [28]. Rubin et al. [29] reported 27 patients who after temporalis or masseter transfer could smile spontaneously without clenching their teeth. If this phenomenon were more predictable and reproducible, it would be very useful in the management of patients with facial paralysis [30].

Based on the results of this study with a limited number of patients, the orthodromic temporalis transposition through an intraoral approach proved satisfactory. This technique could be applied safely and effectively on a larger number of cases with long-standing facial palsy and may well be tested to augment facial nerves grafting in cases with either recent or old facial palsies.

#### Conclusion:

Orthodromic temporalis tendon transfer through an intraoral approach to reanimate the lower face in long-standing facial paralysis cases is a relatively

easy procedure to perform. It has distinct advantages compared with other forms of facial reanimation. This procedure takes into account the advantages of the orthodromic transposition in terms of better muscle excursion and power. Thus, allowing for good movement of the corner of the mouth with restoration of the smile, in addition to symmetry at rest. It is performed in a minimally invasive manner and eliminates the facial asymmetry typically produced by antidromic temporalis transfer.

#### REFERENCES

- 1- Lexer E. and Eden R.: *Über die chirurgische Behandlung der peripheren Facialis Lahmung*. Beitr. Klin. Chir., 73: 116, 1911. Quoted from Baker D.C.: Facial paralysis. In McCarthy J.G., ed.: *Plastic Surgery*. Philadelphia: WB Saunders. Vol 3. of 8: P 2284, 1990.
- 2- Viterbo F. and Faleiros H.R.: Orthodromic transposition of the temporal muscle for facial paralysis: Made easy and better. *Journal of Craniofacial Surgery* 16 (2): 306, 2005.
- 3- May M. and Drucker C.: Temporalis muscle for facial reanimation (a 13-year experience with 224 procedures). *Archives of Otolaryngology Head & Neck Surgery*, 119: 378, 1993.
- 4- Clark J.M. and Shockley W.W.: Management and reanimation of the paralyzed face. In: Papel I.D., ed.: *Facial plastic and reconstructive surgery*. New York: Thieme, 2002: 660-685.
- 5- Gilles H.D.: Experiences with fascia lata grafts in the operative treatment of facial paralysis. *Proc R. Soc. Med.*, 27: 1372, 1934. Quoted from Baker DC: Facial paralysis. In McCarthy JG, ed.: *Plastic Surgery*. Philadelphia: WB Saunders. Vol 3. of 8: p 2286, 1990.
- 6- Andersen J.G.: Surgical treatment of lagophthalmos in leprosy by Gilles temporalis transfer. *British Journal of Plastic Surgery*, 14: 339, 1961.
- 7- Rubin L.R.: *Reanimation of the Paralyzed Face*. St. Louis: CV Mosby, 1977.
- 8- Baker D.C. and Conley J.: Regional muscle transposition for rehabilitation of the paralyzed face. *Clinics in Plastic Surgery*, 6: 317, 1979.
- 9- May M.: Muscle transposition for facial reanimation. *Facial Plastic Surgery*, 8 (2): 11, 1992.
- 10- McLaughlin C.R.: Surgical support in permanent facial paralysis. *Plastic Reconstructive Surgery*, 11: 302, 1953.
- 11- Breidahl A.F., Morrison W.A., Donato R.R., Riccio M. and Theile D.R.: A modified surgical technique for temporalis transfer. *British Journal of Plastic Surgery*, 49: 46, 1996.
- 12- Labbé D. and Huault M.: Lengthening temporalis myoplasty and lip reanimation. *Plastic Reconstructive Surgery*, 105 (4): 1289, 2000.
- 13- May M.: Muscle transposition for facial reanimation. Indications and results. *Archives of Otolaryngology*, 110 (3): 184, 1984.

- 14- Anderson R.G.: Facial nerve disorders and surgery. Selected Readings in Plastic Surgery, 8 (20): 1-33, 1999.
- 15- Clark J.M. and Shockley W.W.: Management and reanimation of the paralyzed face. In Papel I.D., ed.: Facial plastic and reconstructive surgery. New York: Thieme, 660-685, 2002.
- 16- Freeman B.S.: Review of long-term results in supportive treatment of facial paralysis. Plastic and Reconstructive Surgery, 63: 214, 1979.
- 17- Konior R.J.: Facial paralysis reconstruction with Gore-Tex soft-tissue patch. Archives of Otolaryngology. Head & Neck Surgery, 118: 1188, 1992.
- 18- Byrne P.J., Kim M., Boahene K., Millar J. and Moe K.: Temporalis tendon transfer as part of a comprehensive approach to facial reanimation. Archives of Facial Plastic Surgery, 9 (4): 234, 2007.
- 19- Adams W.M.: The use of the masseter, temporalis and frontalis muscles in the correction of facial paralysis. Plastic and Reconstructive Surgery, 1: 216, 1946.
- 20- Owens N.: Surgical correction of facial paralysis. Plastic and Reconstructive Surgery, 2: 25, 1947.
- 21- Castro Correia P. and Zani R.: Masseter muscle rotation in the treatment of inferior facial paralysis. Plastic and Reconstructive Surgery, 52: 370, 1973.
- 22- Duckert L.G. and Cummings C.W.: The temporalis myofascial dynamic sling. Laryngoscope, 91: 1963, 1981.
- 23- Rubin L.R.: The anatomy of a smile. Its importance in the treatment of facial paralysis. Plastic and Reconstructive Surgery, 53: 384, 1974.
- 24- Paletz J.L., Manktelow R.T. and Chaban R.: The shape of a normal smile: Implications for facial paralysis reconstruction. Plastic and Reconstructive Surgery, 93: 784, 1994.
- 25- Jobe R.P.: A technique for lid loading in the management of lagophthalmos of facial palsy. Plastic Reconstructive Surgery, 53: 29, 1974.
- 26- Casler J.D. and Conlley J.: Simultaneous "dual system" rehabilitation in the treatment of facial paralysis. Archives of Otolaryngology Head & Neck Surgery, 116: 199, 1990.
- 27- Balaji S.M.: A modified temporalis transfer in facial reanimation. International Journal of Oral Maxillofacial Surgery, 31 (6): 584, 2002.
- 28- Cheney M.L., McKenna M.J., Megerian C.A., West C. and Elahi M.M.: Trigeminal neo-neurotization of the paralyzed face. Annals of Otology, Rhinology & Laryngology, 106: 733, 1997.
- 29- Rubin L.R., Rubin J.P., Simpson R.L. and Rubin T.R.: The search for the neurocranial pathways to the fifth nerve nucleus in the reanimation of the paralyzed face. Plastic and Reconstructive Surgery, 103 (6): 1725, 1999.
- 30- Dellon L. and Mackinnon S.E.: Reanimation following facial paralysis by adjacent muscle neurotization: An experimental model in the primate. Microsurgery, 10: 251, 1989.